

Balloon Eustachian tuboplasty: a retrospective cohort study

Schröder, S., Lehmann, M., Ebmeyer, J., Upile, T. & Sudhoff, H.

Department of Otolaryngology, Head and Neck Surgery, Bielefeld Academic Teaching Hospital, Münster University, Bielefeld, Germany

Accepted for publication 29 March 2015

Clin. Otolaryngol. 2015, 40, 629–638

Background: Eustachian tube dysfunction is regarded as a 'black box' term, reflecting a spectrum of dysfunction. The key to its diagnosis and management is in identifying the aetiology and exact pathophysiology of the dysfunction.

Design: We present our retrospective 5-year results for the technique of transnasal endoscopic balloon dilatation of the cartilaginous part of the Eustachian tube, balloon Eustachian tuboplasty (BET). The indication for treatment is chronic obstructive Eustachian tube dysfunction.

Main outcome measures: Preoperatively, the Eustachian tube score (ETS) was obtained by a clinico-objective assessment involving tubomanometry (TMM) and reported patient symptom. The measurements were repeated 1, 2, 3, 4 and 5 years postoperatively.

Setting: Tertiary referral centre.

Participants: A total of 622 patients (1076 ears) were treated with BET.

Results: One year after treatment, the Eustachian tube score improved from 3.13 (\pm 2.47 SD) to 5.75 (\pm 2.76 SD). The Eustachian tube score improved significantly in 73% of ears. The average Eustachian tube score 2 years after treatment improved from 2.65 (\pm 2.89 SD) to 6.26 (\pm 3.07 SD). In 82% of patients, the Eustachian tube score improved significantly at 5 years. The subjective satisfaction of the patients was approximately 80%.

Conclusions: Our long-term results suggest that BET is a safe and feasible treatment for chronic obstructive Eustachian tube dysfunction with a success rate of more than 70%. This study has important implications for other Eustachian tube-related clinical entities, such as glue ear management (adults and children), continued grommet insertion and tympanomastoid surgery outcomes.

Introduction

Chronic Eustachian tube dysfunction has multiple causes and is a difficult condition to treat. Analysis of the literature suggests that, despite the multifactorial nature of its aetiology, a common finding in Eustachian tube dysfunction is mucosal and/or cartilaginous functional obstruction of the lower portion of the tube (Fig. 1). This obstruction is potentially amenable to obturation and dilatation. Eustachian tube dysfunction, particularly obstructive dysfunction, results in inadequate ventilation of the middle ear and mastoid bone. This may lead to a myriad of symptoms and diseases, such as recurrent acute serous otitis media or chronic otitis media, occasionally with the destruction of the tympanic membrane and associated ossicles, and eventually cholesteatoma formation. Reduced hearing or deafness can also occur.^{1–3} The incidence of Eustachian tube dysfunction

in adults is approximately 1%.⁴ Almost 40% of children up to the age of 10 develop at least a temporary dysfunction of the Eustachian tube.^{5,6} Studies in children and adults have demonstrated that Eustachian tube dysfunction is present in up to 70% of patients undergoing tympanoplasty for chronic otitis media or cholesteatoma.^{7,8} Infantile dysfunction results from adenoid tissue and mucosal swelling due to infection. Other causes are as follows: hyperplastic tonsils, causing reactive inflammation of the tubal lymphatics and lumen obstruction; an abnormal softness of the tubal cartilage, allowing closure rather than stenting open the lumen by elastic recoil; a faulty mucociliary clearance or muscular dysfunction. In adults, the pathogenesis may be chronic infection, allergy, laryngopharyngeal reflux (LPR), primary mucosal disease, dysfunction of the dilation mechanism or anatomical obstruction.^{9,10} The typical symptoms of Eustachian tube dysfunction are a feeling of pressure in the ears that intensifies with changes in the atmospheric pressure and the inability to successfully perform Valsalva's manoeuvre. Long-term Eustachian tube dysfunction may lead to persistent or recurrent middle ear effusion, retraction of the tympanic membrane, chronic otitis media or even cholesteatoma. Otologists generally agree that Eustachian tube

Correspondence: Professor Dr. med. Holger Sudhoff, FRCS, FRCPath, Department of Otolaryngology, Head and Neck Surgery, Bielefeld Academic Teaching Hospital, Affiliated to Bielefeld and Münster University, Teutoburger Str. 50, 33604 Bielefeld, Germany. Tel.: +49 521 581 3301; Fax: +49 521 581 3399; e-mail: holger.sudhoff@rub.de

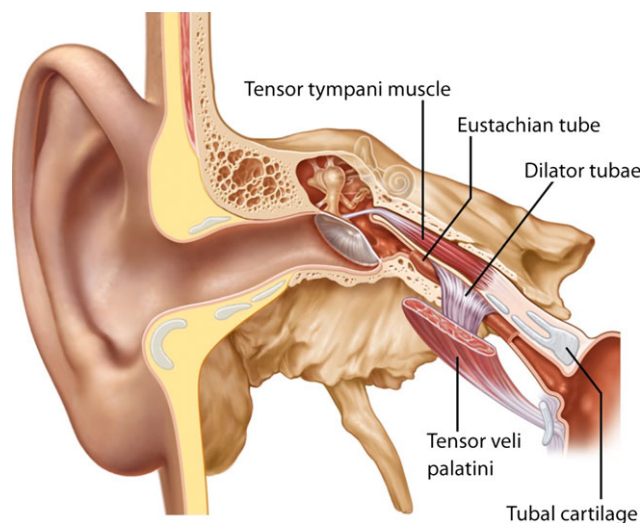


Fig. 1. Right coronal temporal bone view including the external and middle ear, the cartilaginous and bony portion of the Eustachian tube, and the adjacent muscles.

function is critical to the outcome of middle ear surgery.^{11,12} However, reliable diagnostic tools and effective therapeutic approaches for Eustachian tube dysfunction are lacking.⁷ Notably, treatments aimed at the underlying causes are not available; instead, management aims to bypass the Eustachian tube using grommets.

The established treatment options for chronic obstructive Eustachian tube dysfunction are mostly symptomatic; myringotomy, aspiration and grommet insertion is the treatment of choice for most otologists.^{13,14} The grommet acts as a temporary surrogate Eustachian tube but, because of its prosthetic nature, is susceptible to extrusion and may act as a potential site of infection. Nevertheless, grommet insertion remains the most common ENT operation in the world.

Balloon dilation Eustachian tuboplasty (BET) via the nasopharyngeal opening of the Eustachian tube is a novel treatment approach designed to treat a common root cause. The aim of this minimally invasive intervention is the dilatation and opening of the cartilaginous part of the Eustachian tube. The technique was applied clinically for the first time in February 2009 after extensive preliminary tests,¹⁵ has been adopted by more than 110 ENT departments in Europe and after NICE review (IP194)¹⁶ is now available for further UK studies.

Preliminary investigations

We previously investigated the feasibility of balloon dilation of the Eustachian tube as a first step in the possible treatment of Eustachian tube dysfunction in an earlier study.^{17,18} Our concept is analogous to the dilatation of the lumen of arterial vessels with percutaneous transluminal coronary angioplasty or balloon sinuplasty. After formal institutional and ethics approval of pilot and clinical studies, the effect of balloon dilatation was investigated in cadavers to ensure its safety as a technique. To verify the correct placement of the balloon catheter, high-resolution CT scans with 3D reconstructions and detailed microslices temporal bone histology were performed. The Eustachian tubes of five human cadavers were treated with a 600- μ m-diameter balloon catheter. In the Eustachian tube, the balloon was inflated with a pressure of 10 bars for 120 s (Fig. 2a and b). Subsequently, we performed CT scans and histopathological studies, finding no obvious complications. The balloon could be reliably and correctly placed in the Eustachian tube (Fig. 3). Histology indicated no injury of the internal carotid artery, but microtears were visible in the mucosa of the cartilaginous part of the Eustachian tube.¹⁷

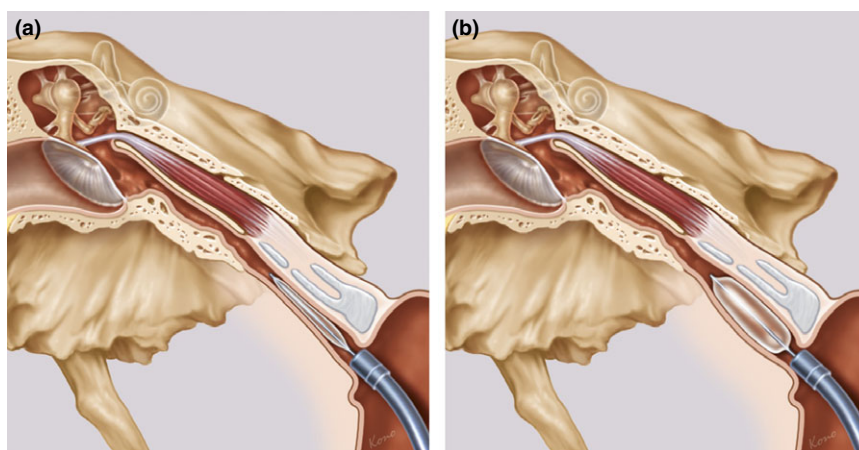


Fig. 2. Coronal cross section of the catheter insertion tool positioned in the cartilaginous portion of the right Eustachian tube. (a) uninflated, (b) inflated.

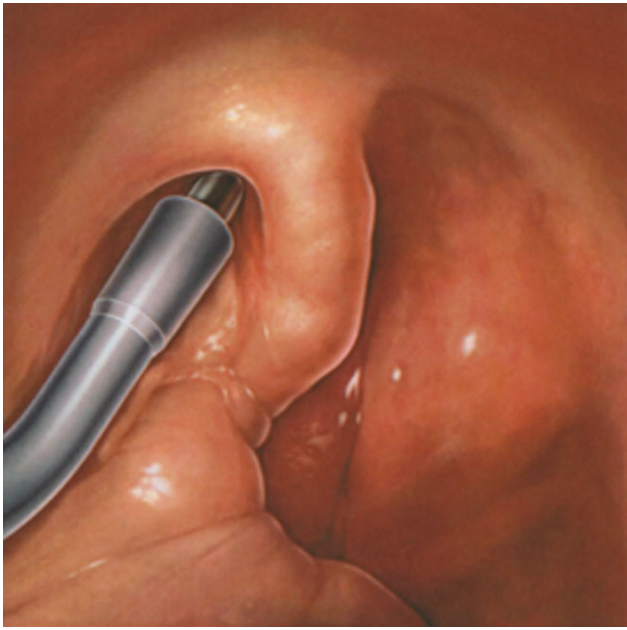


Fig. 3. Contralateral 70° endoscopic view of the catheter insertion tool positioned in the epipharyngeal ostium of the right Eustachian tube.

We subsequently modified our method for the Eustachian tuboplasty using a softer and more flexible balloon and specific insertion tool (Fig. 2b). In our first clinical study in 2009, we offered BET to eight adults with chronic Eustachian tube dysfunction and a history of tympanoplasties with a follow-up of 8 weeks¹⁸. This first clinical study suggested the feasibility of balloon dilation of the Eustachian tube as an iterative step towards the treatment of Eustachian tube dysfunction.

Patient selection

BET is offered in our department as a unilateral or bilateral procedure in adult patients and children from the age of 7 years. Initially, patients were included who had suffered from symptoms of chronic obstructive Eustachian tube dysfunction or had undergone one or more middle ear surgeries as a result of previously undiagnosed Eustachian tube dysfunction. BET was indicated in chronic-persistent OME as a consequence of obstructive tube dysfunction. Currently, we suggest treatment with balloon dilatation in symptomatic patients with an ETS (Eustachian tube score) ≤ 5 or $\text{ETS-7} \leq 7$ ¹⁹ and the presence of at least one of the following clinical symptoms of chronic obstructive ET dysfunction: an uncomfortable sensation of pressure in the ears, especially with changes in atmospheric pressure (e.g. on an airplane); an inability to perform Valsalva's manoeuvre; chronic otitis media with effusion; an obvious adhesive

process; a flat line in the tympanogram (type B); or early recurrence of retraction after tympanoplasty (repair of the tympanic membrane).

Before treatment, a careful history is taken from each patient with questions concerning pressure sensation in the ear, problems with pressure equalisation in the ear, possibility of performing Valsalva's manoeuvre and Toynbee's manoeuvre and their history of diseases and surgeries of the ear. We found the ETDQ-7 questionnaire published by McCoul *et al.* in 2012 to be a helpful additional diagnostic instrument for the evaluation of Eustachian tube function. The questionnaire may also be valuable in follow-up examinations to monitor treatment success.²⁰ The clinical examination includes a complete ENT examination with Valsalva and Toynbee, tympanometry, audiometry and tubomanometry.

Tubomanometry

To measure treatment effectiveness, we tried to find a practicable tool for a more objective description of the ET function. The tubomanometry (TMM) was described by Estève in 2001.^{21,22} We used the modified tubomanometry technique by Estève (Spiggle & Theis, Overath, Germany). The concept of TMM is based upon the controlled delivery of defined pressures of 30, 40 and 50 mbar to the nasopharynx through a nasal applicator. Pressure curves for the nasopharynx and ear canal are displayed on the monitor of the TMM device, and various measuring values are calculated (Fig. 4). The opening latency index (R value) reflects the latency between pressure application in the nasopharynx and the measurement of a pressure change in the ear canal.²³ This latency quantifies Eustachian tube function: immediate opening ($R < 1$) indicates good Eustachian tube function and late opening ($R > 1$) indicates restricted Eustachian tube function. No opening (R negative or not measurable) indicates complete obstruction of the Eustachian tube. TMM is feasible in intact and perforated eardrums, and it delivers specific information about the dynamic of the Eustachian tube.

Eustachian Tube Score

To compare preoperative and postoperative results using statistical analysis, we developed a summation point score for Eustachian tube function that relies on anamnestic data and TMM results (Table 1). The ETS is a rating system incorporating clinical symptoms and TMM results (i.e. subjective and objective data). The clinical symptoms 'clicking sound when swallowing' and 'positive Valsalva's manoeuvre' are rated with 0 points for 'never', 1 point for 'sometimes' and 2 points for 'always'. For TMM results at 30,

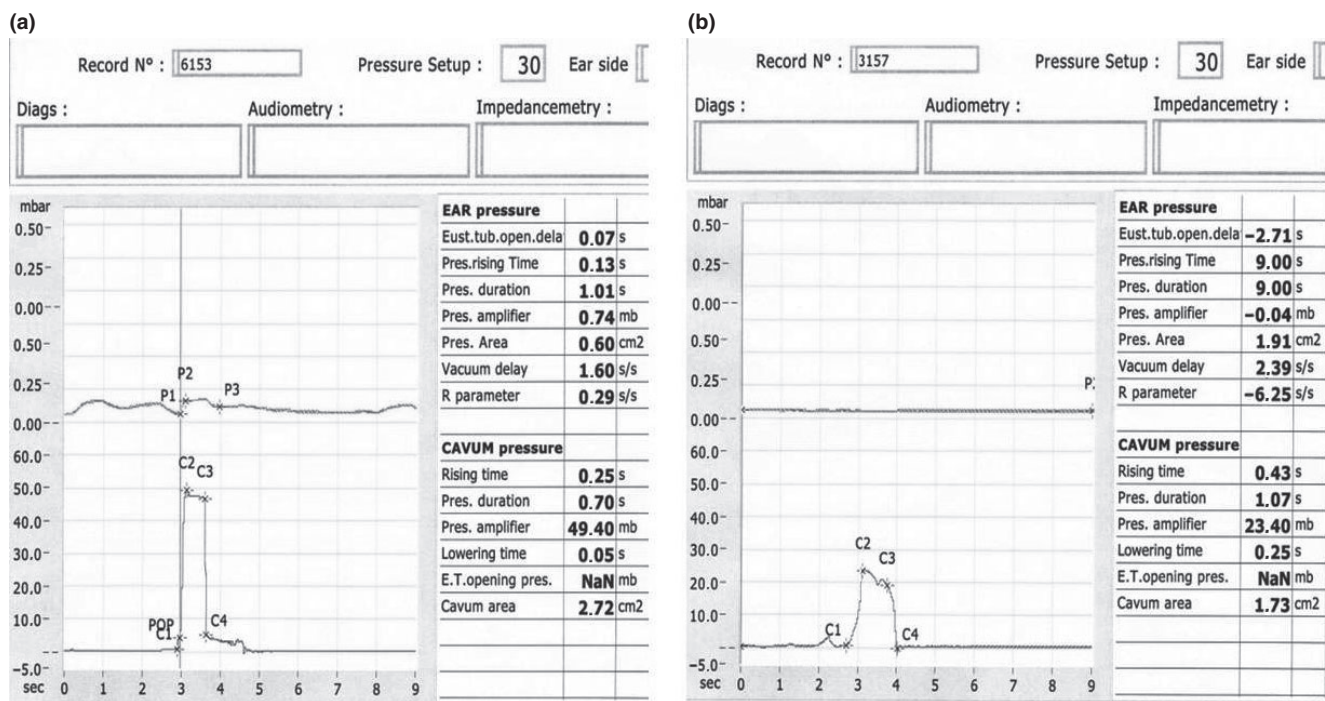


Fig. 4. Tubomanometry (TMM) by Estève. Pressure curves of the epipharynx and the ear canal. (a) immediate opening ($R < 1$), indicating good Eustachian tube function; (b) no opening (not measurable), indicating obstruction of the Eustachian tube.

Table 1. Eustachian tube score range 0–10

Symptoms	2 points	1 point	0 points
Clicking noise by swallowing	Always	Infrequent	No clicking
Clicking noise by Valsalva	Always	Infrequent	No clicking
TMM 30 mbar	$R < 1$	$R \geq 1$	No P
TMM 40 mbar	$R < 1$	$R \geq 1$	No P
TMM 50 mbar	$R < 1$	$R \geq 1$	No P

TMM = tubomanometry.

40 and 50 mbar, immediate opening of the ET ($R \leq 1$) is 2 points, delayed opening ($R > 1$) is 1 point and no opening (negative or not measurable R) is 0 point. The points from these five tests were summed, resulting in an ETS of 0 (worst value) to 10 (best value). Thus, the ETS gives a quantitative assessment of Eustachian tube function and allows interindividual, as well as prospective, comparisons. The ETS is independently reproducible and correlates with patient-reported symptoms and outcomes.¹⁹

Imaging

We studied 284 preoperative high-resolution CT scans of the temporal bone before unilateral or bilateral BET. We found minor bony carotid canal dehiscences in only 18 patients

(6.3%), but the clinical outcome was unaffected and the procedure carried out uneventfully. In three patients (four Eustachian tubes, 1.1% of patients, 0.8% of Eustachian tubes), balloon dilation could not be performed due to difficulties advancing the balloon catheter. In the light of current literature, our data suggest that fear of internal carotid injury during balloon dilation is disproportionate.²⁴ This conclusion was corroborated by Tisch *et al.*, who evaluated head CT scans of 1000 patients and found no dehiscence of the carotid canal. The bony carotid canal has a thickness of 1.02 mm.²⁵ Moreano *et al.* also examined 1000 temporal bones and found a carotid canal dehiscence in 7.7% and a micro dehiscence in 7.4%. A total of 15.5% of the carotid canals had only a thin bony coverage.²⁶ Our procedure is intended to only treat the cartilaginous part of the Eustachian tube; therefore, a CT scan, which has a high radiation exposure, was deemed unnecessary, thus protecting our paediatric patients from unwarranted radiation exposure. From March 2013, we no longer perform routine CT scans prior to BET.

BET method

BET is an interventional method for treating chronic obstructive Eustachian tube dysfunction. Under general anaesthesia, a balloon catheter is inserted transnasally into the nasopharyngeal ostium of the Eustachian tube with

endoscopic visualisation (Fig. 3). The balloon is inflated with saline to 10 bars for 120 s inside the cartilaginous part of the Eustachian tube. At 10 bars, the balloon has predefined dimensions of 2.0 cm in length and 3.28 mm in diameter. After 120 s, the catheter is deflated and removed.

We used three different ways of performing BET with the catheter insertion tool. The catheter insertion tool was mostly positioned transnasally in the nasopharyngeal Eustachian tube ostium and the catheter advanced into the cartilaginous part of the Eustachian tube. The insertion tool prevents tubal insertion deeper than 3.5 cm. For endoscopic visualisation, we used either a 45° or 70° Hopkins endoscope in the contralateral nostril or a 30° Hopkins endoscope in the ipsilateral nostril. In the minority of cases, for example, in patients with very deviated nasal septums, a 70° endoscope was used transorally to visualise the nasopharynx. For illumination, a xenon light source was used. The catheter insertion tool offers three differently angled extensions matching the endoscopes' angulations: 30°, 45°, and 70° (Fig. 5). Visualisation is also possible with a flexible endoscope or an angled mirror normally used in adenoidectomy.

Close observation of the extraction phase of the catheter from the Eustachian tube after dilation provides feedback as to whether the catheter was really inside the tube and not kinked in the mucosal folds of the nasopharynx (e.g. Rosenmueller's fossa).

Postoperative nasal steroid spray was encouraged for approximately 6 weeks for all patients. The intention was to reduce the development of scars and restenosis after treatment. Thus far, nasal steroid spray seems to have no direct influence on chronic obstructive Eustachian tube dysfunction.²⁷

Results

Between February 2009 and February 2014, 622 patients (male : female \approx 1 : 1) were treated for chronic obstructive




Fig. 5. New insertion tools with three angled extensions: 30°, 45° and 70°, colour coded according to Hopkins endoscopes.

Eustachian tube dysfunction. A total of 1076 BET procedures were performed. The youngest patient was 7 years old and the oldest was 84 years old. Fifty children (7–17 years old) have been treated to date. The non-CT protocol delineated our lower age inclusion criterion as the age of Eustachian tube length maturation (7 years). We performed revision surgery in 10.5% of all balloon dilatations (68 patients). The vast majority of included patients exhibited no opening of the Eustachian tube in TMM at 30, 40 and 50 mbar. The average ETS for all patients before treatment was 3.51 (\pm 2.66), indicating moderate-to-severe obstructive Eustachian tube dysfunction.

BET is easy to perform and is usually a bloodless and straightforward procedure. We recommend performing BET under general anaesthesia with endoscopic visualisation of the nasopharynx.

Eustachian tube function 2 months after treatment

We obtained data from 506 of the 1029 balloon dilatations 2 months after the treatment, adding up to a follow-up rate of 49%. The average ETS for these patients improved from 3.15 (\pm 2.54 SD) before the procedure to 5.37 (\pm 2.71 SD) after the procedure. Wilcoxon's test revealed a significant improvement ($P \leq 0.001$) in 357 cases (71%).

Eustachian tube function 1 year after treatment

Of the 671 dilatations performed about 1 year ago, 188 (28%) were included in the follow-up analysis. The average ETS improved from 3.13 (\pm 2.47 SD) to 5.75 (\pm 2.76 SD). The ETS improved significantly ($P \leq 0.001$) in 138 of the 188 cases (73%; Fig. 6).

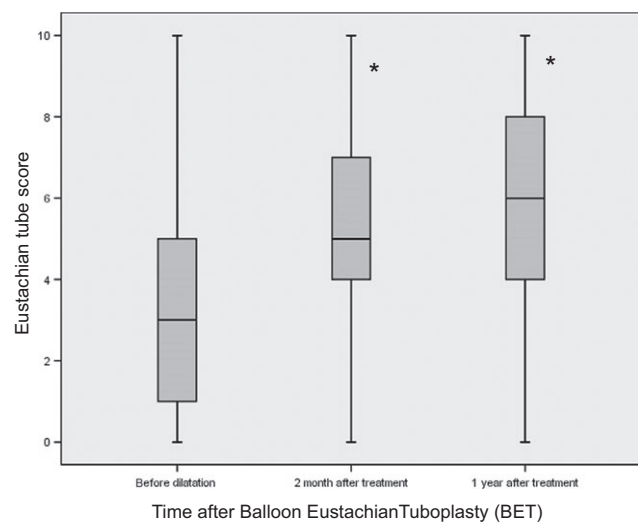


Fig. 6. Eustachian tube score (see Table 1) at the 1-year follow-up ($n = 188$). * $P \leq 0.001$ in Wilcoxon's test.

Eustachian tube function 2 years after treatment

A total of 34 of the 344 dilatations performed more than 2 years ago and were included in the two-year follow-up analysis (10% follow-up rate). The average ETS at this time point improved from 2.65 (\pm 2.89 SD) to 6.26 (\pm 3.07 SD). In 28 of the 34 cases (82%), the ETS improved significantly ($P \leq 0.001$) (Fig. 7). These data show that we concentrated on patients with an ETS ≤ 5 for our first treated patients.

Eustachian tube function 3 years or more after treatment

The data obtained from 11 of 119 ears (9%) 3 years after treatment and 2 of 17 ears 4 years after treatment indicate that the effect of the Eustachian tube dilatation may decrease. The average ETS 3 years after treatment improved from 2.36 (\pm 2.69 SD) to 5.27 (\pm 3.82 SD). In 9 of the 11 cases (82%), the ETS improved significantly ($P \leq 0.032$; Fig. 8). After 4 years, the ETS decreased to 1 in both cases we could evaluate.

Subjective satisfaction

Approximately 2 years after the treatment, we asked the first 89 patients treated (154 dilatations) about their experiences and subjective satisfaction using a questionnaire. Thirty patients returned the questionnaire. The patients were asked to describe the degree of improvement and their satisfaction with the treatment. No improvement was noted by 27% of the patients and 20% were dissatisfied with the outcome. However, 47% of the patients were free of any complaints and 26% reported an improvement after the procedure.

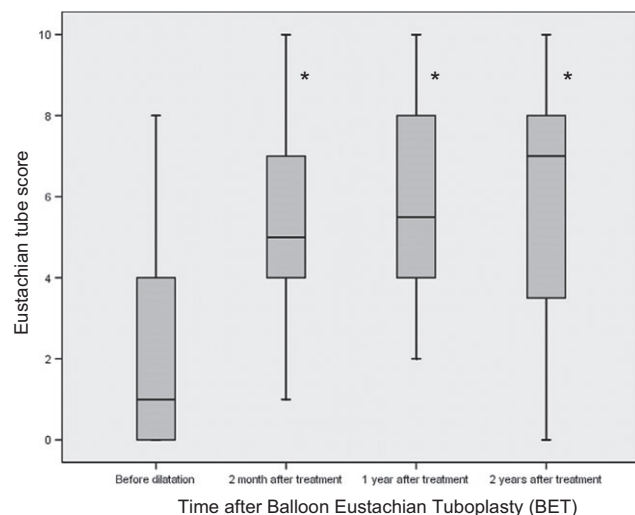


Fig. 7. Eustachian tube score (see Table 1) at the 2-year follow-up ($n = 34$). $*P \leq 0.001$ in Wilcoxon's test.

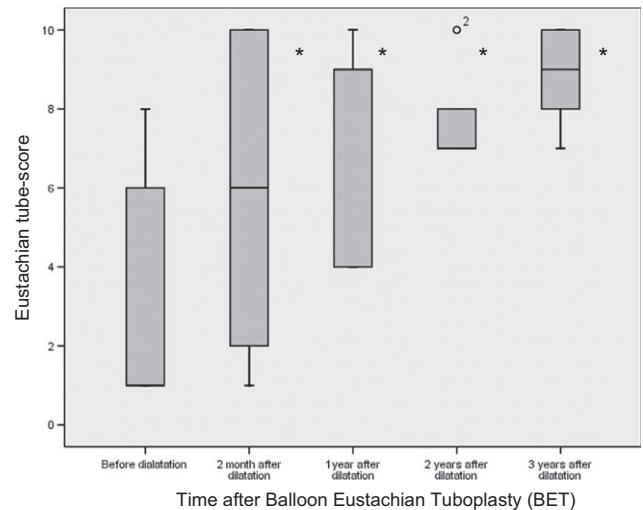


Fig. 8. Eustachian tube score (see Table 1) at the 3-year follow-up ($n = 11$). $*P \leq 0.05$ in Wilcoxon's test.

Among all patients who answered the questionnaire, 60% were satisfied with the result of the treatment and 20% were only completely satisfied for the first few months after treatment. Interestingly, the subjective opinion of the patients matched our objective data in 57% of cases. The validated questionnaire was translated for our patient population into German.²⁸

Complications

We did not observe any serious complications with BET. In only three of the more than 1000 procedures, surgical emphysema within the parotid region was observed as sequelae of a minor mucosal tear in the Eustachian tube. In all three cases, the emphysema was reabsorbed under antibiotic cover and the Eustachian tube healed without permanent damage. Eustachian tube function still improved in all three cases. Minor bleeding and a temporary increase in pre-existing tinnitus for 2 weeks after the procedure were the other adverse effects we observed. A patulous Eustachian tube has never been observed after BET.

Discussion

Eustachian tube dysfunction has often been regarded as a 'black box' in which the function of the system remains unclear. A spectrum of dysfunction has become increasingly clear, and identifying the aetiology and exact pathophysiology is key to its diagnosis and treatment. However, many difficulties still exist in the assessment of Eustachian tube dysfunction. No gold standard exists for diagnosis, which makes it even harder to judge the success of any treatment.

Over the years, a variety of different therapeutic approaches for chronic obstructive Eustachian tube dysfunction have been proposed, ranging from nasal decongestion and steroids to golden tube conductor wires (historic), grommet insertion and tympanoplasty. Convincing concepts of causal therapy with a minimally invasive action and long-lasting effects have been missing. Recent publications now focus upon balloon catheter dilation of the Eustachian tube and laser tuboplasty.^{29–38}

Caffier, Kujawski and Poe reported that laser Eustachian tuboplasty seems to be a feasible, safe and in suitable cases effective procedure. Laser Eustachian tuboplasty can be a good addition to endoluminal treatment of chronic obstructive Eustachian tube dysfunction, such as in hypertrophic torus tubarius. This technique has been reported to be successful in almost 70% of cases after 1 year, but it is a complex surgery requiring endoscopic CO₂ laser.^{29–31}

We first presented the new technique for minimally invasive surgery on the cartilaginous Eustachian tube for the improvement of Eustachian tube dysfunction in 2008.³² The procedure is a causal treatment for chronic Eustachian tube dysfunction; it is easy to perform and usually takes 15 min under general anaesthesia with endoscopic visualisation of the nasopharynx.

However, uncertainties exist regarding the use of the procedure in children due to obvious anatomical differences. We have been conservative in our application of the technique, despite its wide applicability, and only treat children over the age of 7 years. However, Tisch *et al.* presented 105 cases of successful intervention in paediatric patients from the age of 12 months without any complications.³³ We, however, suggest BET only as second line therapy in younger children.

Even in adults the most suitable candidates for this procedure are difficult to define, as well as the cut-off levels for the procedure. Patient selection is the most critical point and requires more clinical data. In our opinion, there are four main groups of indication for the BET: (i) sensation of pressure in the ears, especially with changes in atmospheric pressure and inability to perform Valsalva's manoeuvre (ii) chronic otitis media with effusion (iii) adhesive process (iv) early recurrence of retraction after tympanoplasty. Depending on the findings of the ear drum and the results of the tympanometry and tubomanometry, the rates of success of the balloon dilatation might vary. This is an important avenue for further investigations. The data presented in this publication contain the results of the BET from all the different causes of chronic obstructive ET dysfunction as mentioned above. Retrospective subgroup analysis is underway looking at the following subgroups: (i) sensation of pressure in the ears, especially with changes in atmospheric pressure and inability to perform Valsalva's manoeuvre (ii)

chronic otitis media with effusion (iii) adhesive process (iv) early recurrence of retraction after tympanoplasty and (v) chronic otitis media with perforation of the eardrum. Although the number of patients was relatively small, we observed positive effects of BET on chronic otitis media with effusion in terms of complete resolution of the effusion at the 2-month follow-up visit. Minor retractions of the tympanic membrane often resolved after BET, and even small perforations that were persistent for at least 1 year before BET healed in some cases without further surgical treatment. These effects should be further investigated.

Considering the current data indicating a slightly less positive postoperative outcome when Eustachian tube dilatation is combined with other surgical procedures (e.g. septum or sinus surgery), we recommend a two-stage concept with septum or sinus surgery first and then BET surgery as a second stage if Eustachian tube dysfunction persists. Performing BET 2 months prior to tympanoplasty seems reasonable if obstruction of the Eustachian tube is present.

The results of our investigations show a significant improvement of the function of the ET 2 month after BET in 71%, 1 year after BET in 73% and in 82% about 2 years after BET was performed. The number of the patients with a complete follow-up was quite low. This reduces the outcomes' significance; hence, one cannot determine that the data are representative for the whole patient cohort. This applies to the data from patients with 3- to 4-year follow-up, which may be appreciated as mere observations but from which significance cannot yet be drawn. We decided to include the revision surgery in this study, but at the time of the revision, the subjects were declared as lost-to-follow-up for the first procedure. Tisch and co-workers reported about the clinical experience with 320 interventions with the same balloon. About 71.4% of the patients reported about a subjective strong improvement of their complaints. Before the BET, only 7.2% could perform the Valsalva's manoeuvre and after the dilatation 90% had a positive Valsalva.³⁴

Poe and co-workers described a similar method of BET with a modified catheter in 2011. They performed the dilatation with a 6- or 7-mm-diameter and 16-mm-long sinuplasty balloon with 12 atmospheres for 2 min. Eleven patients with otitis media with effusion and negative Valsalva's manoeuvre were treated. Postoperatively, all treated patients were able to perform Valsalva's manoeuvre.³⁵ When discussing the results of BET, one has to keep in mind that there are two slightly different BET catheters used for the procedures. Hence, when comparing the published results of BET, one has to distinguish between the two catheters. However, BET currently seems to be a promising option in the treatment of Eustachian tube dysfunction. Silvola *et al.* reported in 2014 about 41 Eustachian tube (ET)

operations in subjects with otitis media with effusion and/or atelectasis, curve type B or C tympanograms and inability to inflate their middle ears by Valsalva manoeuvre. None of the ears required new tympanostomy tubes and subjective symptoms were relieved. Tympanometry results showed overall improvement.³⁶ These results indicate that patients with otitis media with effusion and/or atelectasis could have a great benefit from the balloon dilatation. Wanscher *et al.* classified their 34 treated patients in 4 different subgroups: Class 1 (if they could equalise middle ear pressure during a normal Valsalva's test), Class 2 (if they required a prolonged Valsalva's manoeuvre), Class 3 (if only a test with the Otovent could make air flow to the middle ear) and Class 4 (if no air passage through the Eustachian tube could be achieved). A significant effect of the treatment with the balloon dilatation was documented when measuring for example audiometry, tympanometry, Toynbee's test. It is described that patients with atelectatic ear drums were not helped by the treatment.³⁷ This seems contrary to our experiences and the results of Silvola *et al.*³⁶ Therefore, generally accepted criteria for the diagnosis and measurement of the success of the treatment of chronic obstructive ET dysfunction are essential to measure outcomes.

While it is difficult to compare the results of the different studies, it is desirable to agree on defined indication groups for the BET and defined instruments to measure the outcome of the procedures. The standard test for the evaluation of the pressure conditions behind the tympanic membrane and indirectly for the function of the ET is the tympanometry. It is easy and fast to perform and widely available for each ENT specialist. But tympanometry and as well audiometry alone cannot sufficiently describe the function of the ET. Questionnaires such as the Glasgow Benefit Inventory (GBI) do not provide objective measurements of the ET function, but they can help to objectify the subjective improvement after treatment. Bast *et al.* used the GBI in 30 patients treated with the BET. The analysis revealed significant improvements in the total score as well as in the general and physical health of subjects.³⁸ We found the EDTQ-7 questionnaire helpful for the standardised evaluation of symptoms before and after treatment.²⁰ We translated the EDTQ-7 into German and now routinely use it before treatment to support the BET intervention indications and after treatment to monitor the outcomes.²⁸ As an addition and to combine subjective and objective data, we developed the ETS-7 as a new instrument for the facilitation of diagnosis and follow-up in patients with chronic obstructive ET dysfunction. Based on our preceding experience, we extended the ETS with two additional items: tympanometry and objective Valsalva measurements resulting in the ETS-7. The test-retest reliability revealed a

correlation of 0.87. ETS-7 receiver operating characteristic (ROC) analysis – with reference to the EDTQ-7 score – resulted in an area under the curve (AUC) of 0.64. Our analysis considered the essential criteria of ETD as comparative tools: typical clinical complaints and at least two of three conditions: a pathologic EDTQ-7,²⁰ a type B/C tympanometry and a positive independent expert evaluation. The corresponding AUC was 0.98. Chronic obstructive ETD was identified at a cut-off of 7 with a sensitivity of 96% and a specificity of 96% using the novel ETS-7.¹⁹ Confoundingly, the comparison of the ETS and the subjective opinion of the patients matched only in 57%. The symptoms and complaints may not always correlate with tubal function, or perhaps in some cases, the indications for BET may have been to poor.

BET currently seems to be a promising option in the treatment of Eustachian tube dysfunction. Several independent publications about this new treatment option also report a measurable improvement of the ET function. Nevertheless, the publications are confounding as they contain a variety of different inclusion criteria and different instruments to measure the results of the BET. The comparability is low. We are in need of more specific and comparable data. The use of BET has important implications as an adjunct in the optimisation of Eustachian tube function for the treatment of 'Glue Ear' in children (i.e. grommet insertion) and improvement of the long-term results of tympano-mastoid surgery by recovering middle ear ventilation. The results of the present study demonstrate that BET is a safe and effective method that can significantly improve Eustachian tube function in the majority of cases of chronic obstructive Eustachian tube dysfunction.³⁹

Conclusion

Based on our results, the BET procedure is minimally invasive, easy to perform and effective in more than 70% of cases. Since 2009, over 12 000 BET procedures have been performed using the BET-Catheter[®] in our department and the more than 110 otologic departments on the European mainland who have adopted the procedure. Further prospective controlled clinical trials are desirable to prove the effectiveness of the technique.

Keypoints

- Balloon Eustachian tuboplasty (BET) has been performed in a large patient cohort.
- BET was effective in more than 70% of included patients.
- No severe side effects or complications were observed.

Declarations

The author has no conflict of interest and there was no financial support. S.Schröder, M. Lehmann, J. Ebmeyer, and H. Sudhoff received fees for sessions and financial support for research projects.

References

- Bluestone C.D. & Klein J.O. (1996) Otitis media, atelectasis, and Eustachian tube dysfunction. In *Pediatric Otolaryngology*, 3rd edn, Bluestone C.D., Stool S.E. & Kenna M.A. (eds), pp. 182–187. WB Saunders, Philadelphia
- Mewes T. & Mann W. (1998) Function of the eustachian tube in epitympanic retraction pockets. *HNO* **46**, 914–918
- Bhutia M., Williamson I.G. & Sudhoff H. (2011) Cholesteatoma. *BMJ* **342**, 596–98
- Browning G.G. & Gatehouse S. (1992) The prevalence of middle ear disease in the adult British population. *Clin. Otolaryngol. Allied Sci.* **17**, 317–321
- Gudziol V. & Mann W.J. (2006) Chronic eustachian tube dysfunction and its sequelae in adult patients with cleft lip and palate. *HNO* **54**, 684–688
- Goldman J.L., Martinez S.A. & Ganzel T.M. (1993) Eustachian tube dysfunction and its sequelae in patients with cleft palate. *South. Med. J.* **86**, 1236–1237
- Todd N.W. (2000) There are no accurate tests for eustachian tube function. *Arch. Otolaryngol. Head Neck Surg.* **126**, 1041–1042
- Choi S.H., Han J.H. & Chung J.W. (2009) Pre-operative evaluation of Eustachian tube function using a modified pressure equilibration test is predictive of good postoperative hearing and middle ear aeration in type 1 Tympanoplasty patients. *Clin. Exp. Otorhinolaryngol.* **2**, 61–65
- Takahashi H., Honjo I. & Fujita A. (1996) Endoscopic findings at the pharyngeal orifice of the eustachian tube in otitis media with effusion. *Eur. Arch. Otorhinolaryngol.* **253**, 42–44
- Poe D.S. & Gopen Q. (2009) Eustachian tube dysfunction. In *Ballenger's otorhinolaryngology: head and neck surgery*, Snow J.B., Wackym P.A. & Ballenger J.J. (eds), pp. 201–208. BC Decker, Lewiston, New York
- Podoshin L., Fradis M., Malatsky S. *et al.* (1996) Tympanoplasty in adults: a five-year survey. *Ear Nose Throat J.* **75**, 149–152
- Dorrie A., Dommerich S. & Pau H.W. (2003) Early postoperative middle-ear ventilation – risk for the transplant or guarantee for aeration of the tympanic cavity? *Laryngorhinootologie* **82**, 102–104
- Leuwer R. & Koch U. (1999) Anatomy and physiology of the auditory tube. Therapeutic possibilities in chronic disorders of tubal function. *HNO* **47**, 514–523
- Sudhoff H., Schröder S., Reineke U. *et al.* (2013) Therapy of chronic eustachian tube dysfunction. Evolution of applied therapies. *HNO* **61**, 477–482
- Ockermann T (2009) *Die Ballondilatation der Eustachischen Röhre zur Behandlung der obstruktiven Tubendysfunktion*. HNO Klinik Bielefeld, Dissertation Ruhr-Universität Bochum, Bochum, Germany.
- IP 914. IP overview: Balloon dilatation of the Eustachian tube. Nice Assessment March 2011.
- Ockermann T., Reineke U., Upile Ebmeyer J. *et al.* (2010) Balloon dilatation Eustachian tuboplasty (BET): a feasibility study. *Otol Neurotol* **31**, 1100–1103
- Ockermann T., Reineke U., Upile T. *et al.* (2010) A clinical study: balloon dilatation eustachian tuboplasty (BET). *Laryngoscope* **120**, 1411–1416
- Schröder S., Lehmann M., Sauzet O. *et al.* (2015) A novel diagnostic tool for chronic obstructive Eustachian tube dysfunction -The Eustachian Tube Score. *Laryngoscope* **125**, 703–708
- McCoul E.D., Anand V.K. & Christos P.J. (2012) Validating the clinical assessment of eustachian tube dysfunction: the eustachian tube dysfunction questionnaire (ETDQ-7). *Laryngoscope* **122**, 1137–1141
- Esteve D., Dubreuil C., Della Vedova C. *et al.* (2001) Evaluation par tubomanometrie de la fonction d'ouverture tubaire et de la réponse tympanique chez le sujet normal et chez le sujet porteur d'une otite séro-muqueuse chronique. *J. Fr. ORL* **50**, 223–231
- Ars B. & Dirckx J.J. (2003) *Tubomanometry*. Kugler, Den Haag
- Sudhoff H., Ockermann T. & Mikolajczyk R. (2009) Clinical and experimental considerations for evaluation of Eustachian tube physiology. *HNO* **57**, 428–435
- Abdel-Aziz T., Schröder S., Lehmann M. *et al.* (2014) Computed tomography prior to balloon eustachian tuboplasty – A true necessity? *Otol Neurotol* **35**, 635–638
- Tisch M., Störrle P., Danz B. *et al.* (2013) Role of imaging before Eustachian tube dilation using the Bielefeld balloon catheter. *HNO* **61**, 488–491
- Moreano E.H., Paparella M.M., Zeltermann D. *et al.* (1994) Prevalence of carotid canal dehiscence in the human middle ear: a report of 1000 temporal bones. *Laryngoscope* **104**, 612–619
- Gluth M.B., McDonald D.R., Weaver A.L. *et al.* (2011) Management of eustachian tube dysfunction with nasal steroid spray: a prospective, randomized, placebo-controlled trial. *Arch. Otolaryngol. Head Neck Surg.* **137**, 449–455
- Schröder S., Lehmann M., Sudhoff H. *et al.* (2014) Assessment of chronic obstructive Eustachian tube dysfunction: evaluation of the German version of the Eustachian tube dysfunction questionnaire. *HNO* **62**, 162–164
- Caffier P.P., Sedlmaier B., Haupt H. *et al.* (2011) Impact of laser Eustachian tuboplasty on middle ear ventilation, hearing, and tinnitus in chronic tube dysfunction. *Ear Hear.* **32**, 132–139
- Poe D.S., Grimmer J.F. & Metson R. (2007) Laser Eustachian tuboplasty: two-year results. *Laryngoscope* **117**, 231–237
- Kujawski O.B. & Poe D.S. (2004) Laser Eustachian tuboplasty. *Otol. Neurotol.* **25**, 1–8
- Schröder S., Reineke U., Lehmann M. *et al.* (2013) Chronic obstructive eustachian tube dysfunction in adults. Long-term results of balloon Eustachian tuboplasty. *HNO* **61**, 142–151
- Tisch M., Maier S., Hecht P. *et al.* (2013) Bilateral Eustachian tube dilatation in infants: an alternative treatment for persistent middle ear functional dysfunction. *HNO* **61**, 492–493
- Tisch M., Maier S. & Maier H. (2013) Eustachian tube dilation using the Bielefeld balloon catheter: clinical experience with 320 interventions. *HNO* **61**, 483–7
- Poe D.S., Silvola J. & Pyykkö I. (2011) Balloon dilation of the cartilaginous eustachian tube. *Otolaryngol. Head Neck Surg.* **144**, 563–569

- 36 Silvola J., Kivekäs I. & Poe D.S. (2014) Balloon dilation of the cartilaginous portion of the eustachian tube. *Otolaryngol. Head Neck Surg.* **151**, 125–130
- 37 Wanscher J.H. & Svane-Knudsen V. (2014) Promising results after balloon dilatation of the Eustachian tube for obstructive dysfunction. *Dan Med J.* **61**, A4818
- 38 Bast F., Frank A. & Schrom T. (2013) Balloon dilatation of the Eustachian tube: postoperative validation of patient satisfaction. *ORL J. Otorhinolaryngol. Relat. Spec.* **75**, 361–365
- 39 Miller BJ & Elhassan HA (2013) Balloon dilatation of the Eustachian tube: an evidence based review of case series for those considering its use. *Clin. Otolaryngol.* **38**, 525–532